

Case Report

Need for a Change – Extended-FAST to Extended Diaphragmatic-FAST

Sasikumar Mahalingam*, Gunaseelan Rajendran, Vishwanath Balassoundaram, Balamurugan Nathan

Department of Emergency Medicine, Jawaharlal Institute of Postgraduate Medical Education and Research, Puducherry, India

Abstract

Post-traumatic hypoxia can be due to different causes, namely airway problems, pneumothorax, hemothorax, lung contusion, flail chest, traumatic diaphragmatic injuries (TDI), aspiration due to low sensorium, a respiratory paradox in cervical spine injury, severe hypotension, etc.,. It is a great challenge to identify the cause of hypoxia in a trauma setting because the contributing factors can be multiple or can be a remote cause, which is often missed out. Here, we describe a 50-year-old female who presented to our emergency department with Post-traumatic hypoxia whose sensorium, blood pressure, chest X-ray, E-FAST computed tomography of brain, and other baseline investigation were completely normal, diagnosed later as TDI with the help of diaphragmatic ultrasound and computed tomography of thorax.

Keywords: Extended Diaphragmatic - FAST, Post-traumatic hypoxia, Traumatic diaphragmatic injury

INTRODUCTION

Post-traumatic hypoxia in our patient was due to traumatic diaphragmatic injuries (TDI), which is usually missed in around 70%^[1] of cases and among them 7.2% ends up in complication. Delay in diagnosis can increase mortality up to 30%.^[2] Although there was a short delay initially, we managed to clinch the diagnosis with help of ultrasound which was confirmed by computed tomography (CT)-thorax and thereby major complications have been avoided in our patient. A high index of suspicion is needed to diagnose TDI among all thoracoabdominal injuries. Thus, incorporating diaphragmatic ultrasound in our routine E-FAST in thoracoabdominal injuries can help us in suspecting and diagnosing TDI early.

CASE REPORT

A 50-year-old female with an alleged history of road traffic accident (pedestrian vs. two-wheeler) came to our emergency department (ED) with history of loss of consciousness for 30 min, breathlessness and lower abdominal pain. The patient had low saturation (92% on room air) with the normal respiratory examination and positive pelvic compression on

the primary survey. Other vitals were PR = 96/min, blood pressure = 140/70 mmHg, and RR = 20/min. E-FAST and chest X-ray (CXR) were normal. Pelvis X-ray showed left inferior pubic ramus fracture. Hence, the patient was treated with oxygen support and pelvic binder. On the secondary survey, the patient had sutured scalp lacerations, upper and lower abdomen abrasions. The patient's CT brain was normal. Hence, our provisional diagnosis was pelvic fracture/post-traumatic dyspnea (cause unknown).

Both clinical and ultrasound examination could not find the cause of desaturation. Meanwhile, patient's saturation dropped to 85%. We planned to repeat E-FAST examination along with diaphragmatic ultrasound using a curvilinear probe (5–7 MHz), which showed absent left diaphragmatic excursion [Figure 1]. Lung assessment during E-FAST using linear probe (5–12 MHz) showed intrathoracic bowel peristalsis [Figure 2a, b and Video 1] which was confirmed with high-resolution CT lung later [Figure 3]. Patient was taken up for surgery and treated finally.

Address for correspondence: Dr. Sasikumar Mahalingam, Department of Emergency Medicine and Trauma, Jawaharlal Institute of Postgraduate Medical Education and Research, Puducherry, India. E-mail: sasiempub@gmail.com

Received: 22-07-2020 Revised: 26-09-2020 Accepted: 08-10-2020 Available Online: 17-12-2020

Video available on: www.jmuonline.org

Access this article online

Quick Response Code:



Website:
www.jmuonline.org

DOI:
10.4103/JMU.JMU_104_20

This is an open access journal, and articles are distributed under the terms of the Creative Commons Attribution-NonCommercial-ShareAlike 4.0 License, which allows others to remix, tweak, and build upon the work non-commercially, as long as appropriate credit is given and the new creations are licensed under the identical terms.

For reprints contact: WKHLRPMedknow_reprints@wolterskluwer.com

How to cite this article: Mahalingam S, Rajendran G, Balassoundaram V, Nathan B. Need for a change – Extended-FAST to extended diaphragmatic-FAST. J Med Ultrasound 2021;29:215-7.

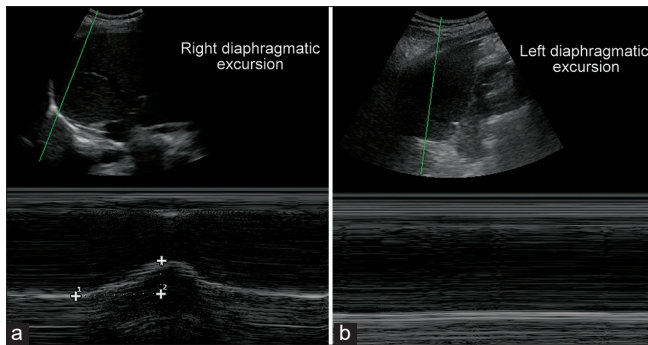


Figure 1: (a) Right diaphragmatic assessment shows normal diaphragmatic excursion. (b) Left diaphragmatic assessment shows absent diaphragmatic excursion (Using curvilinear probe, 5–7 MHz)

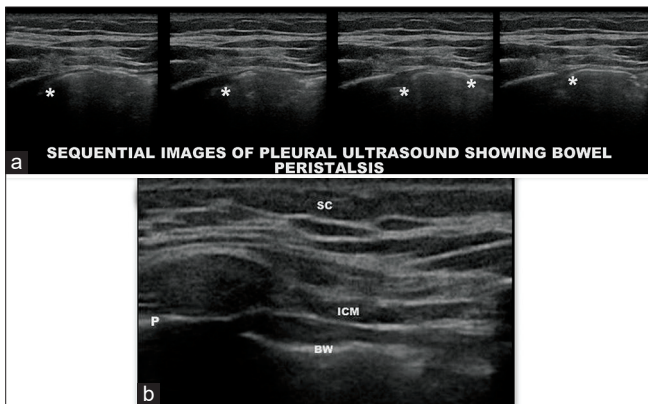


Figure 2(a and b): Sequential images of bowel peristalsis in pleural/lung ultrasound using linear probe (5–12 MHz) (video part has been uploaded in video section) (SC: Subcutaneous tissue, ICM: Intercostal muscle, P: Pleura, BW/*: Bowel wall)

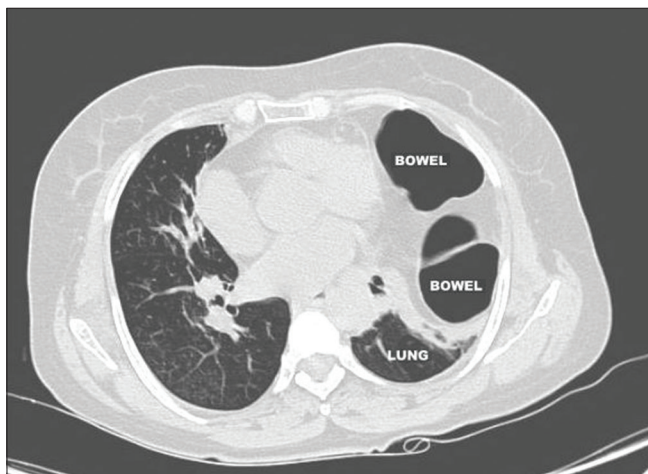


Figure 3: Computed tomography thorax showing left side diaphragmatic injury with bowel herniation

Initial CXR and respiratory examinations were normal, which blindfolded us not to think beyond the airway and lung injury. This led to the delayed diagnosis of TDI. However, during repeat E-FAST, we did diaphragmatic assessment which showed absent left diaphragmatic excursion. Thus,

incorporating diaphragmatic ultrasound along with E-FAST could avoid the delayed diagnosis of TDI.

DISCUSSION

TDI accounts for <1% of all traumatic injuries. Incidence of TDI among blunt injuries (1%–7%) is less compared to penetrating injuries (10%–15%). TDI may present initially without any symptoms or signs or may have polytrauma, in which other injuries can dominate the clinical severity, which can deviate our attention away from TDI. Although the incidence is low, mortality among missed or delayed diagnosis is very high. Post-traumatic hypoxia can be due to many causes, among which TDI is often missed out in 70% of cases. The causes of TDI can be due to blunt or penetrating injuries. Studies based on the National Trauma Data Bank (NTDB), the largest trauma registry in the world, have found an overall incidence of TDI of 0.46%.^[3] TDI are relatively rare after blunt injuries when compared to penetrating injuries. Blunt diaphragm rupture usually causes large injury when compared to penetrating injury. In a review of the NTDB, 33% had a blunt mechanism among those with diaphragmatic injury, and 67% had a penetrating mechanism. Compared with penetrating injuries, blunt injuries often have a higher injury severity score.^[3] The mechanism of TDI can be due to increased intraabdominal pressure and shearing/avulsion force in blunt injuries, whereas it is due to the penetrating mechanism in penetrating injuries. Left TDI is common than the right side following blunt injury because of two reasons: (a) esophageal hiatal weakness. (b) Buffering effect of the liver in the right hemidiaphragm. Three phases of TDI are: (a) acute diaphragmatic injury, (b) delayed phase of visceral herniation, and (c) late obstructive phase of visceral content.

TDI is classified according to the American Association for the Surgery of Trauma organ injury scale.

- Grade I: Contusion
- Grade II: Laceration ≤ 2 cm
- Grade III: Laceration 2–10 cm
- Grade IV: Laceration >10 cm; tissue loss ≤ 25 cm²
- Grade V: Laceration and tissue loss >25 cm².

The diagnosis can be delayed during the initial phase for various reasons, namely initial small diaphragmatic tear, lack of suspicion, lack of sensitivity of basic investigations, delay in appropriate investigation, etc., which can lead to long-term effects, respiratory symptoms or reduced pulmonary capacity. A high index of suspicion needs to be maintained because delayed diagnosis is associated with an increased risk for herniation and strangulation of abdominal organs, which can be life-threatening. TDI should be kept in mind in any blunt or penetrating thoracoabdominal injuries. The various investigations that can be done to suspect and diagnose TDI are CXR, diaphragmatic ultrasound, CT chest, and magnetic resonance imaging (MRI). A high index of suspicion combined with repeated and selective radiologic evaluation is necessary for early diagnosis. Among this ultrasound has a special

mention as it can be used bedside for unstable patients. It has an added advantage of real-time assessment, repeatability, no radiation exposure, and can be incorporated within routine E-FAST.

The literature search revealed only about 27%–60% of left-sided injuries, and 17% of right-sided injuries could be diagnosed by initial CXR.^[4] Normal or nonspecific CXR are seen in 20%–50% of all patients with TDI. The sensitivity of CXR for detecting TDI with a hernia is up to 94%.^[5] The missing rate of diaphragmatic rupture on CXR ranges from 12% to 66%, with the risk of a late visceral herniation. Serial CXR is recommended in case of suspicion based on the mechanism of trauma. CXR features that may suggest TDI are diaphragmatic outline irregularity, elevated diaphragm, mediastinal shift without pulmonary cause, nasogastric tube above hemidiaphragm, intrathoracic bowel contents with or without collar sign and compression atelectasis of the lower lobe.^[6] CT signs of TDI are diaphragmatic discontinuity, dangling diaphragm sign, collar sign, intrathoracic herniation of viscera, dependent viscera sign and sinus cut-off sign.^[7]

During E-FAST, simple diaphragmatic interrogation using sonographic B mode and M mode can be done, which can be used as a rule-in test for suspecting TDI.^[8,9] Modified E-FAST or ED-FAST (E-FAST + Diaphragmatic ultrasound) should be used in all thoracoabdominal injuries routinely to suspect TDI. Sonographic features that may suggest TDI are poor diaphragmatic excursion, elevated/floating diaphragm, absent liver sliding sign, ribs absent organ sign (nonvisualized spleen, heart), thoracic spleen sign, thoracic peristalsis sign and discontinuity/absent hyperechoic curvilinear line above liver, spleen.^[9,10] However, TDI should be confirmed finally using CT/MRI imaging.

Supportive treatment modalities, namely oxygen support, positive pressure ventilation, nasogastric tube bowel decompression, can be done in the ED. Surgical repair remains the definitive management. Hence from our case report, we would like to emphasize that initial clinical findings and CXR could be misleading us away from the thought process of TDI. Hence, ED-FAST should be routinely used to suspect TDI in

the early disease course, thereby, we can initiate the proper diagnostic investigation, and management plans early.

Declaration of patient consent

The authors certify that they have obtained all appropriate patient consent forms. In the form, the patient has given her consent for her images and other clinical information to be reported in the journal. The patient understands that her name and initials will not be published and due efforts will be made to conceal identity, but anonymity cannot be guaranteed.

Financial support and sponsorship

Nil.

Conflicts of interest

There are no conflicts of interest.

REFERENCES

1. Stark P, Jacobson F. Radiology of thoracic trauma. *Curr Opin Radiol* 1992;4:87-93.
2. Vilallonga R, Pastor V, Alvarez L, Charco R, Armengol M, Navarro S. Right-sided diaphragmatic rupture after blunt trauma. An unusual entity. *World J Emerg Surg* 2011;6:3.
3. Fair KA, Gordon NT, Barbosa RR, Rowell SE, Watters JM, Schreiber MA. Traumatic diaphragmatic injury in the American college of surgeons national trauma data bank: A new examination of a rare diagnosis. *Am J Surg* 2015;209:864-8.
4. Iochum S, Ludig T, Walter F, Sebbag H, Grosdidier G, Blum AG. Imaging of diaphragmatic injury: A diagnostic challenge? *Radiographics* 2002;22:S103-16.
5. Hanna WC, Ferri LE, Fata P, Razek T, Mulder DS. The current status of traumatic diaphragmatic injury: Lessons learned from 105 patients over 13 years. *Ann Thorac Surg* 2008;85:1044-8.
6. Bosanquet D, Farboud A, Luckraz H. A review diaphragmatic injury. *Respiratory Medicine CME*. 2009;2:1-6.
7. Desir A, Ghaye B. CT of blunt diaphragmatic rupture. *Radiographics* 2012;32:477-98.
8. Blaivas M, Brannam L, Hawkins M, Lyon M, Sriram K. Bedside emergency ultrasonographic diagnosis of diaphragmatic rupture in blunt abdominal trauma. *Am J Emerg Med* 2004;22:601-4.
9. Bonatti M, Lombardo F, Vezzali N, Zamboni GA, Bonatti G. Blunt diaphragmatic lesions: Imaging findings and pitfalls. *World J Radiol* 2016;8:819-28.
10. Tjhia J, Noor JM. Beyond E-FAST scan in trauma: Diagnosing of traumatic diaphragmatic rupture with bedside ultrasound. *Hong Kong J Emerg Med* 2018;25:163-5.